

Nouvelles tendances en rhinoplastie

New trends in rhinoplasty

Braccini F.¹
(Nice)

Résumé

La rhinoplastie est une procédure chirurgicale majeure et complexe. L'objectif de cette rhinoplastie moderne est de corriger des disgrâces cosmétiques sans modifier l'apparence ou la personnalité. Il s'agit d'une procédure hautement artistique, où chaque modification apportée peut impacter les volumes adjacents. Elle doit s'appréhender comme une véritable sculpture avec le souci permanent de respecter les proportions. Le respect ou l'amélioration de la fonction respiratoire est également essentiel. Les techniques ont évoluées, devenant moins agressives et plus conservatrices. Nous développons depuis de nombreuses années les concepts de mini rhinoplastie. La médecine esthétique a récemment donné un nouveau souffle à la rhinoplastie, en offrant des solutions temporaires pour modifier un nez sans chirurgie. Ces techniques de rhinoplastie médicale s'appuient sur l'utilisation de produits de comblement ou fillers pour modifier ou sculpter les volumes du nez, et sur l'utilisation de toxine botulique pour agir efficacement sur la dynamique nasale. Dans cet article nous décrivons l'évolution de notre approche chirurgicale et la place de la rhinoplastie médicale.

Mots-clés : Rhinoplastie à minima, rhinoplastie médicale, toxine botulique, produits de complements, acide hyaluronique.

Summary

Rhinoplasty is one of the most interesting and complex aesthetic surgeries. Its main aesthetic and artistic goal is to enhance beauty by creating a harmonious natural looking face. There isn't one and only standard rhinoplasty procedure, but as many rhinoplasties as there are individual patients. Everyone seeks for more wellbeing and self-confidence in the quest of beauty. Along with facial aesthetic, rhinoplasty aims to improve the nasal breathing function, another important factor for patients. Rhinoplasties have evolved in much the same way as other plastic surgeries: more radical; more preserving of the function; and more simple both in concept and in procedure. Rhinoplasty procedures are simplified with the objective of reducing surgical trauma and optimising down time. It remains a surgical act, but newer fields of aesthetic medicine modify its philosophic and technical approach. Furthermore, approaches which propose an external approach and large dissection are now becoming less common. The development of aesthetic medicine is also one of the most recent and important «evolution corner» in the indication strategy. We can now modify and «sculpt» the nose by using fillers, with or without the use of botulinum toxin. In this article, the author describes his personal surgical strategies and the position of non-surgical solutions in the modification of the nose appearance.

Key-words: Minimal rhinoplasty, medical rhinoplasty, botulinum toxin, fillers, hyaluronic acid.

INTRODUCTION

Rhinoplasty is one of the most interesting and complex aesthetic surgical procedures as proved by the number of secondary rhinoplasties.

It's main aesthetic and artistic goal is to enhance beauty by creating a harmonious natural looking face (1, 2).

There isn't one and only standard rhinoplasty procedure, but as many rhinoplasties as there are individual patients.

Behind the quest of beauty everyone intends to improve well being and self confidence.

Along with the facial aesthetics, rhinoplasty aims to improve the nasal breathing function, another important factor for patients. Rhinoplasties have evolved in much the same way as other plastic surgeries: more radical; more preserving of the function; and more simple both in concept and in procedure

Rhinoplasties procedures evolve and are simplified with the objective of reducing surgical traumas, and optimizing hospitalization time (2).

It remains a surgical act, but the new fields of aesthetic medicine modify its philosophic and technical approach. Thus rare are those today, which propose systematically an external approach and large dissection (3-5).

1. Facial Plastic Surgery, HNS & FPS Riviera Institute, 25 avenue Jean Médecin, 06000 Nice, France. www.braccini.net
E-mail: f_braccini@hotmail.com

Article received: 06/20/11

accepted: 01/16/12

ARTISTIC ANALYSIS

Global analysis of the nose is necessary, but nasal tip is a key point of facial harmony. It is mobile and its mobility depends on the muscle activity of the nasal spine area and nostril area. The nasal position is of great importance for a harmonious facial balance (2).

The shape and position of the nasal tip are defined by static and dynamic anatomical structures that the facial plastic surgeon has to understand for a precise correction and a successful outcome. The skin and its thickness also play a role in the global shape of the tip and its contours. Nasal tip must be analysed as a part of the nose and as an individual anatomical structure.

The base of the nose must be analysed at the same time as it holds the tip in position and is part of the mobile nose. Nasal tips are defined by their projections, rotation and contour.

The tip projection is adequate when 50-60% of the nasal tip (P) is located in front of the vertical line passing through the upper lip (LS) and also when the tip is ideally equal to 60-65% of the nasal length (measured from the naso-frontal angle to the tip).

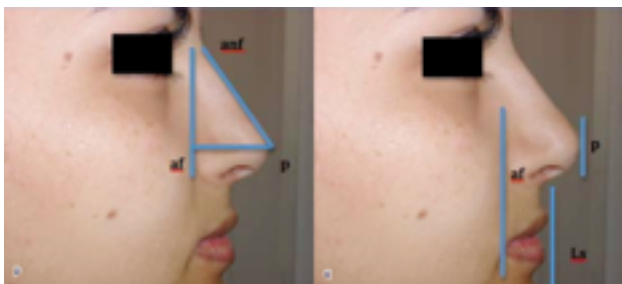

Fig. 1: Simplified tip projection analyse.

In this article we describe the main principles of the minirhinoplasty and at the end we analyze the place of non-surgical procedures.

THE MINI RHINOPLASTY CONCEPT

First described by the French facial plastic surgeons (Pech & Cannoni, Marseille), this technique is fast, simple and reproducible (1, 6). It's a reduced rhinoplasty, which can be done as a day-case surgery.

The method

The experience of the author is based on 1340 mini-rhinoplasty surgical procedures carried out during the last 15 years. Surgical steps of the procedure are hereunder reported.

Indications

The mini-rhinoplasty procedure is indicated in patients with small deformities, particularly in patients with a nasal hump or a hyper-projected noses. The nasal tip should be normal or slightly drooping.

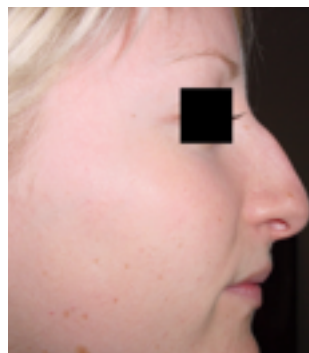

Fig. 2: Example of indication.

The key point in a successful rhinoplasty is the careful preoperative analysis of the patient's concerns and nasal deformities.

The surgeon should proceed further only when a clear, mutual understanding of the rhinoplasty goals has been achieved (fig. 2).

Technique

Surgical steps

Endonasal transcartilaginous approach (fig. 3)

We first locate the caudal and cephalic margins of the lateral crus of the lower lateral cartilage, and make an incision through the vestibular skin only 5 mm to 8 mm cephalic to the caudal margin of the lateral crus.

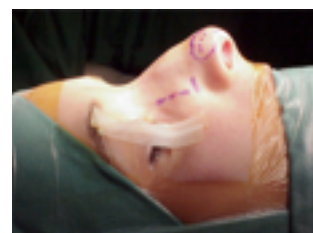
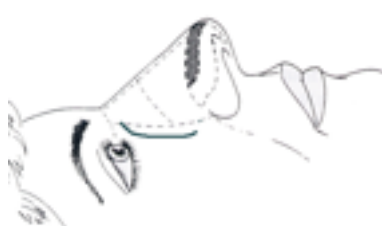
Fig. 3

Tip correction alar cartilages resections (fig. 4)

The caudal part of the alar cartilages is resected by taking care not to injure the mucous membrane.

Resection must be precisely symmetrical to avoid post surgical irregularities.

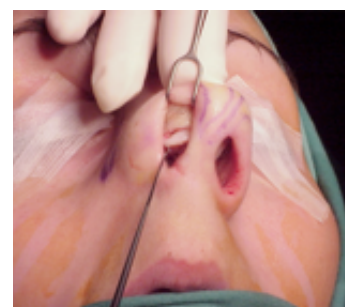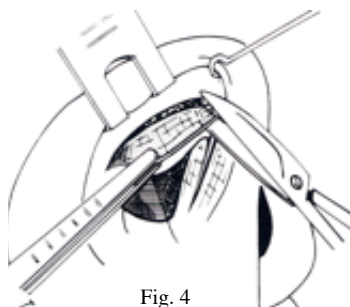


Fig. 4

Septum reduction and hump resection (fig. 5)

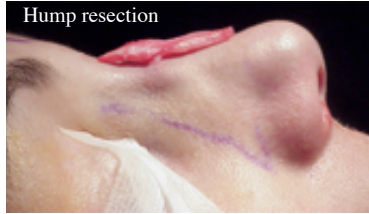
Septal shortening is performed on the full height of the septum from the nasal spine till the upper part of the cartilage. The extent must be estimated according to the shortening and to the desired repositioning.

On average this resection seldom exceeds 4 mm.

Hump resection can be done in 2 steps : scissors at first then with rasps or all in one piece with scissors and osteotome.

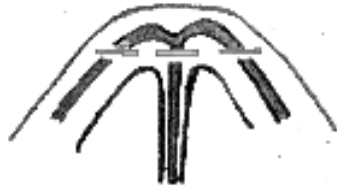
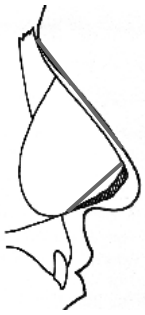
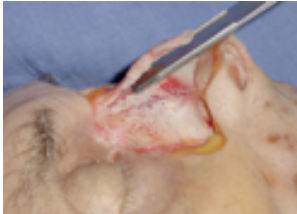Fig. 5



Lateral osteotomies (fig. 6)

Resection of the hump will create an «open roof» appearance, which will then be closed by the mobilization of the fracture sites.

We prefer complete fractures to greenstick fractures which are likely to move later.

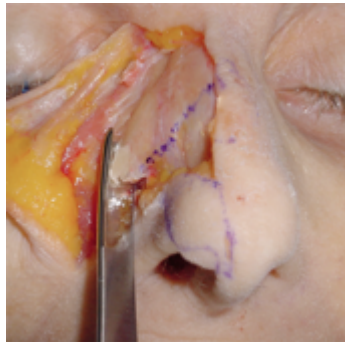
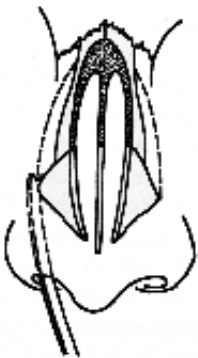

Fig. 6

In fractures (fig. 7)

The mobilization of the osseous fragments must be firm.

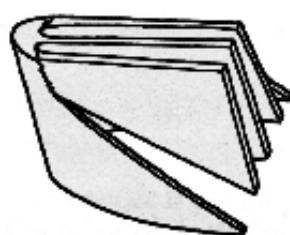
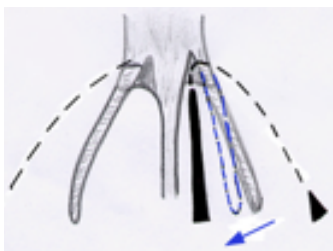


Fig. 7

Nasal base adjustment and sutures (if necessary)

The correction of the alar base is made at the end of the procedure and must be rigorously symmetrical.

New trends in rhinoplasty, Braccini F.

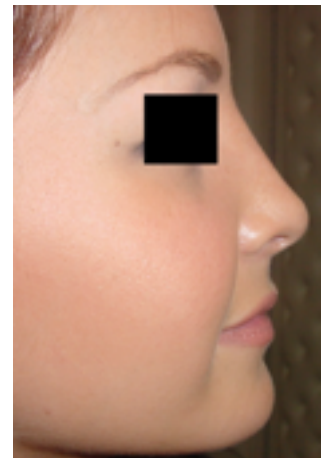
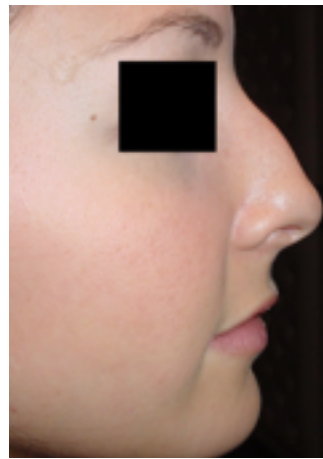
Fig. 8: Mini-rhinoplasty procedure.

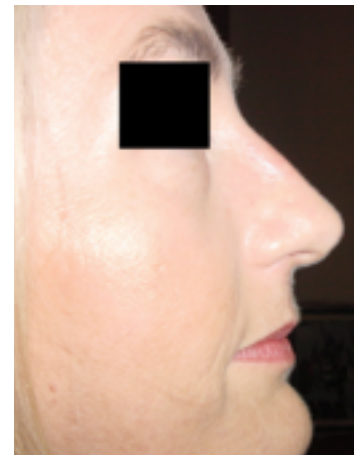
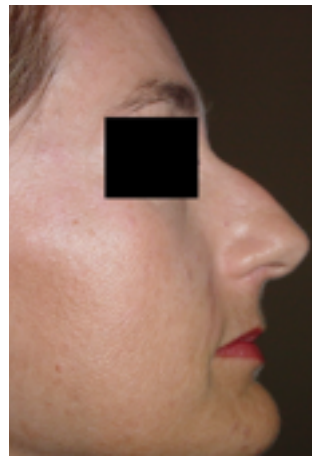


Fig. 9: Mini-rhinoplasty procedure.

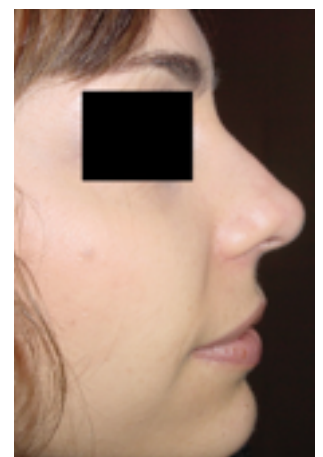
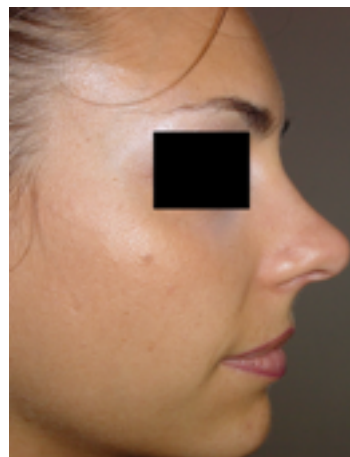

Fig. 10: Over projected and saddle nose. Mini-rhinoplasty with cartilage graft.

Results

The surgical technique is safe and reproducible.

Surgical aesthetic outcomes are excellent. This technique is also indicated in elderly patients seeking facial rejuvenation (figs. 8, 9 & 10).

In summary

The mini-rhinoplasty surgical technique is a minimally invasive procedure with no complications in the postoperative period. The postoperative management of patients undergoing this procedure however is of utmost importance.

THE INTRUSION OF NON SURGICAL PROCEDURE (THE MEDICAL RHINOPLASTY CONCEPT)

The nonsurgical treatment of the nose, or Medical Rhinoplasty, has become one of the star indications in the aesthetic treatment of the face (7). The absence of important mechanical constraints (relatively poor facial dynamics at this level) associated with the stability of the nasal pyramid supports (cartilage and bone) constitute "a particularly favourable terrain" for fillers.

Filling time is thus longer than for other face levels or other face areas.

The satisfaction of our patients has strongly increased. Initially indicated to correct post surgical imperfections, their use has been widely expanded (7, 8).

In many cases the treatment of nasal cosmetic imperfections, associated or not with botulinum toxin injections as in the case of muscles' hyperactivities (depressor septi nasi muscle,...) may be proposed in first intention.

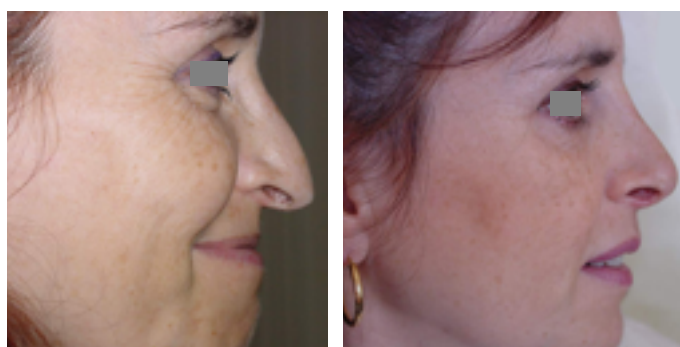

Photo 1

This combination of treatments may also be used as true «medical morphing», for patients who will then take the step towards surgery.

To be clear, these medical techniques never compete with surgery.

Rhinoplasty remains first and foremost a surgical procedure (Photo 1), but the intrusion of fillers and botulinum toxin force us to differently apprehend our treatment indications and our advices.

We will modify: The nose in its own unit and its volumes, which corresponds to nasal volumetry; the nose within the face, which aims to the total harmony of the face (in particular the face and upper lip contact angles). The actual lip and chin treatment with fillers represents, moreover, a true «medical profiloplasty».

We report our experience based on 500 medical rhinoplasties which we have performed from February 2008 to February 2012.

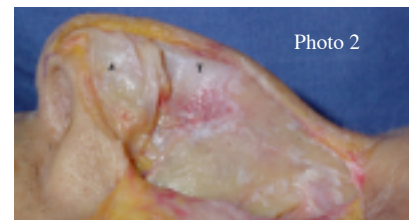


Photo 2

The anatomical basics

They are essential to understand the position of the treatment and to apprehend the possible risks related to the injections. Occupying on average one third of the face, the nose appears as a hollow triangular pyramid with an osteo-cartilaginous structure.

On this osteo-cartilaginous frame, (photo 2) lies like an envelope the perichondrium and the periosteum, the muscles, then the skin. They confer to each individual an anatomical character determining the beauty and the harmony of the face.

We describe:

A fixed portion, formed by the frontal notch, the rising branches of the jawbones, the nasal bones, the superior lateral cartilages and the septum,

A mobile portion, corresponding essentially to the inferior lateral cartilages but also to the superior lateral cartilages (lower portion) which play a crucial role in the nasal valve. The relationship between the fixed and mobile elements of the nose is fundamental in the aesthetic analysis and the medico-surgical project of a rhinoplasty.

The resulting applications of these relationships refer to the morpho-dynamic anatomical concepts.

What is thus fundamental before carrying out a rhinoplasty medical treatment is the knowledge of the nasal frame structures.

The skin, is very rich in sebaceous glands compared to the cartilaginous nose. Its thickness varies significantly according to the areas. Very thin in at the base, it thickens significantly towards the tip. Mobile in the segment with the osseous frame it becomes adherent with the subjacent planes in the portion which corresponds to the cartilages. This adherence is quite important on the lobule. The subcutaneous cellular fabric, weakly developed and almost deficient in fat, forms a quite clear layer only at the level of the mobile nose.

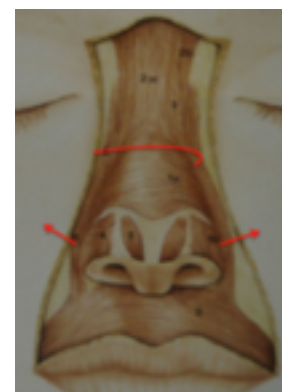
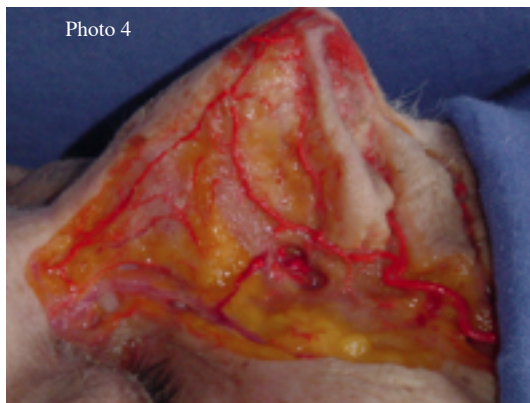

Photo 3

The muscles (photo 3), innervated by the facial nerve. The muscles are connected by the superficial muscular aponeurotic system (SMAS). We describe : elevator muscles, depressors, compressors or dilators of the nostrils. Their role is generally modest apart from the



depressor of the septum (m. depressor septi nasi). They are perfectly accessible to the action of botulinic toxin.

The deep envelop, consists of perichondrium and periosteum which are inter-connected and represent the components of the nasal pyramid.

Vessels and nerves (photo 4)

For the vascularization: If it is very rich, vessels are small in size and safe at the level of the inner canthal area. This vascularization is ensured by the arterial branches of the internal carotid network (ophthalmic art.) and external carotid (Facial art.). The veins drain essentially towards the angular vein but also towards the facial vein.

For the innervation the motor branches arise from the facial nerve and the sensation branches originate from the trigeminal nerve via the external nasal nerve, from the infra-orbital nerve and the naso-lobaire nerve.

The products used

Fillers

We used many filling products in these indications. Taking into account the smoothness of the cutaneous coating, it is necessary that the product injected benefits of a perfect balance between its homogeneity, its diffusion potential in filled areas, and of course its harmlessness.

We never used permanent filler.

Among the many fillers currently available on the market, our choice "was gradually tightened" on the

hyaluronic acid, which can be safely injected in all the areas; at the same time on the level of the fixed nose, but also on the level of the nasal point where the cutaneous tension is very important and where the tolerance of the product must be optimal.

The product must be composed of a highly reticulated hyaluronic acid for a better length stability.

It is necessary to use products with a high tolerance and safety profile (examples : XHA 3* Filorga, Juvederm* Allergan, Teosyal* Teoxane...).

The injection technique (photo 5)

Ideally the procedure is carried out after the application of an anesthetic cream. It can however be undertaken without any anesthesia. The nasal tip is the most significant part. It is necessary to draw up precisely a treatment plan before beginning the injections. Indeed, the nasal cutaneous tension especially at the tip is such, that if too many injections are carried out, the product tends to be extruded.

Several treatment procedures are described:

Filling the hump. The needle is introduced with an obliqueness of 45 ° until bone is reached. It is held by the dominant hand. It is necessary with the thumb and the index of the other hand to carry out a pressure on the side walls of the nasal bones to prevent that the product diffuses laterally. This accidental diffusion of the product can go up to the level of the inner canthus and the lacrimal ducts and must thus be prevented. It is sometimes necessary to fill the naso-frontal angle by a lateral access to properly achieve the treatment of this area. Once the product is injected, it is spread up by a careful massage.

Definition of the tip. As we underlined earlier, it is necessary to avoid multiplying the injection points. One or two points of penetration are thus carried out. They make it possible to radially distribute the whole of the product. (treatment of the nasal tip) the pressure of the injection is essential here. The procedure should be slow and progressive to avoid any cutaneous injury leading to necrosis.

Treatment of the columellar area and opening of the naso-labial angle. It can be carried-out whenever a treatment by botulinum toxin is not associated. The

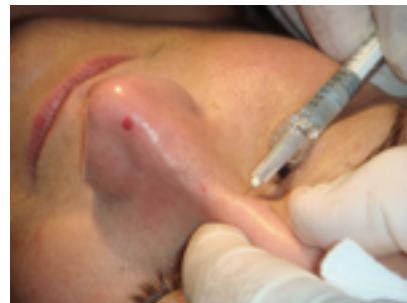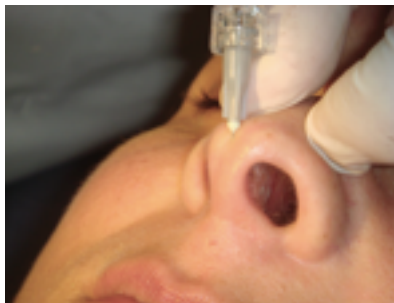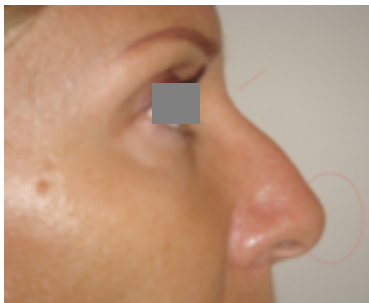


Photo 5

product is injected directly in-depth in order to be deposited in contact with the nasal spine, to open the angle.

Botulinum toxin used in our practice

The botulinum toxin A is the only Botulinum toxin permitted for aesthetic use in any country and in particular:

- Vistabel derived from Botox, Allergan, Irvin California. It can be in packs of 50 or 100U and must be kept in the refrigerator between 2° and 8°.

- Azzalure, approved in Europe recently, and distributed in Europe by Galderma, derives directly from Dysport, Ipsen. It is moderately stronger than Botox; it is found in 125U packs and must be stored in a refrigerator between 2° and 8°.

The different preparations are not interchangeable and the specific units differ, just like their action in the tissues.

Objectives and injections' details (photo 6).

The sites we are going to inject are three:

- two injections of 2.5 U Vistabel or 5U Azzalure in each elevator muscle of lip and nasal alae, tangentially to the nasal alae .

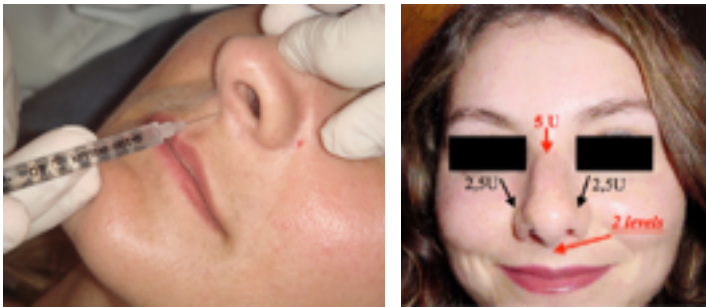

Photo 6

- 5U Vistabel or 10U Azzalure at the nasion level.

- 5U Vistabel or 15U Azzalure at the level of the nasal spine divided into two planes, the first injection must be subcutaneous and the other deeply in contact with the bone.

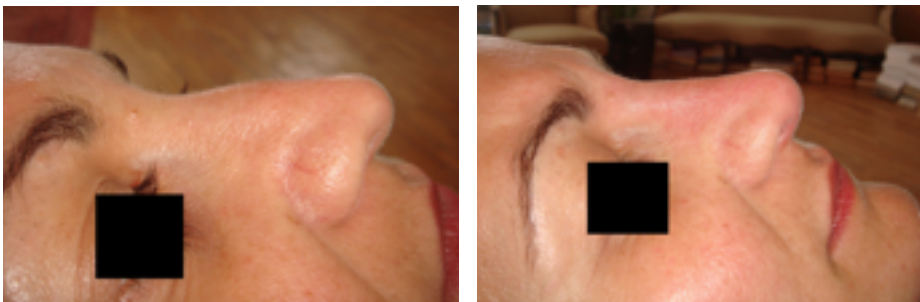

Photo 7: Medical rhinoplasty using fillers for camouflage and botulinum toxin for the tip rotation.

Protocol of treatment

The protocol of treatment is standardized. We carry out a first procedure without over-correction followed by a follow-up on the fifteenth day. If necessary a re-injection or a technical refinement is undertaken. The result is then remarkably stable from 18 to 24 months for the fillers, and 4 months for the botulinum toxin.

Indications (9, 10)

Fillers. All rhinoplasties cannot be accomplished medically! ... Indications arise from the artistic analysis and the realization of the project, just like a surgical rhinoplasty. A data-processing morphing can moreover also be performed before the treatment.

Post surgical rhinoplasty, all the irregularities (asymmetry, deviation...), can be filled with a filler. The indications for these fillings are the same as those of the cartilaginous grafts.

In first intention, "the princeps indication" is the camouflage of osteo-cartilaginous hump. The treatment of the tip and fillings of the contact angles with the lip or the face gives remarkable results.

Botulinum toxin

The control of mimical facial wrinkles using botulinum toxin A (BTxA) is presently a well known process, even in all "Off-Label" uses, but its use at the level of the nasal muscles is more recent.

This new therapeutic target presently opens a very wide application area and, relying on the more general concept that includes facial rejuvenation, it recently plans the use of small doses of BTxA on a regular basis.

The use of botulinum toxin into the nasal muscles should be considered as complementary to the filler.

The contraindications

Fillers: We have never used permanent filler and filler other than hyaluronic acid. In addition it's necessary to respect contraindications specific to the hyaluronic acid (current skin infection, pregnancy...).

The Technical and cosmetic contraindications. The psychological dimension of the nasal modification must always be taken into account. Contraindications are directly related to the psychological and artistic pre-therapeutic analysis. In certain cases, only the surgery will allow a suitable result, particularly in the reduction rhinoplasty.

Botulinum toxin: Contraindications to the use of botulinum toxin are allergy to the drug and infection or inflammation at the proposed injection site(s). Safety for use during pregnancy or lactation has not been established. Therefore, it is prudent to avoid botulinum

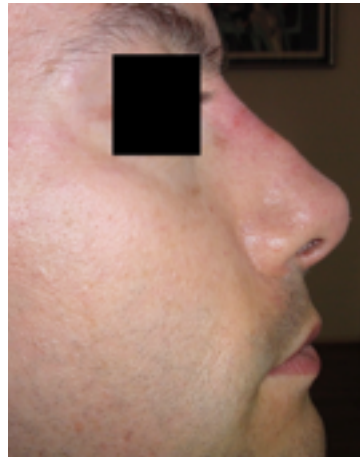
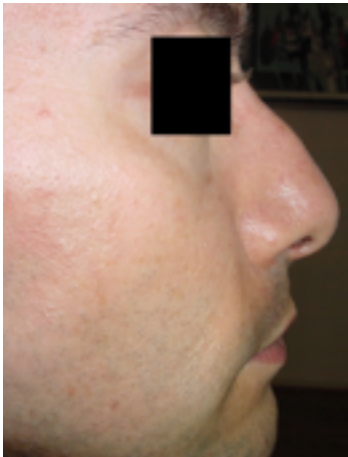
Photo 8: Male camouflaging rhinoplasty.

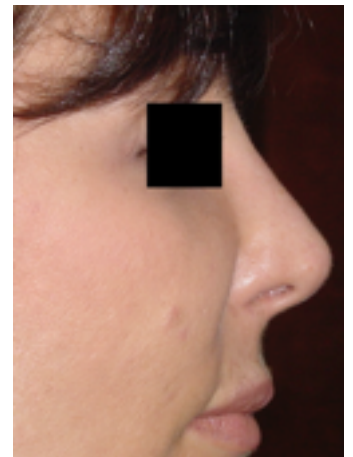
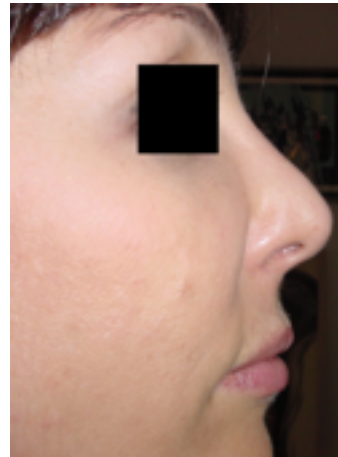

Photo 9: Secondary medical rhinoplasty with fillers in order to harmonize the profile line.

toxin therapy for elective procedures in women of childbearing age until absence of pregnancy or adequate contraception is assured. Relative contraindications include diseases of neuromuscular transmission, coagulopathy (including anticoagulation therapy), and inability of the patient to cooperate. In the more complex disorders, botulinum toxin therapy should not be used unless a skilled interdisciplinary team and sophisticated instrumentation are available to ensure valid diagnosis, state-of-the-art treatment, and appropriate follow-up. The physician administering this drug should be trained in its use and qualified to manage any complications.

CONCLUSION (11, 12)

The soft rhinoplasty or mini rhinoplasty is currently the technique chosen to correct the nose in safe and modern conditions.

Medical rhinoplasty is a new minimally invasive procedure, presenting appreciable results, with a stability higher than treatments in other parts of the face. It is a remarkable procedure.

Technical training and an artistic approach of the indications are required for both procedures.

Bibliography

1. PECH A, CANNONI M. La rhinoplastie personnalisée. *Springer-Verlag Ed, Paris*. 1993:229.
2. ANDERSON J.R., RIES W.R. Rhinoplasty: Emphasizing the external approach. *The American Academy of Facial Plastic and Reconstructive Surgery, Thieme Inc, New York*. 1986.
3. BRACCINI F, DOHAN EHRENFEST DM. Advantages of combined therapies in cosmetic medicine for face ageing: Botulinum toxin filler and mesotherapy. *REV LARYNGOL OTOL RHINOL (BORD)*. 2010;131(2):89-95.
4. BRACCINI F, SABAN Y. Surgical anatomy of the nose. *REV LARYNGOL OTOL RHINOL (BORD)*. 2006;127(1-2):9-13.
5. SABAN Y, BRACCINI F. Rhinoplasties. *Monographie du CCA-Amplifon Edition*. 2002:268.
6. BRACCINI F, PORTA P, THOMASSIN JM. "Mini-rhinoplasty". *REV LARYNGOL OTOL RHINOL (BORD)*. 2006;127(1-2):23-8.
7. BRACCINI F, BERROS P, BELHAOUARI L. Botulinum toxin, description and clinical applications in the treatment of the face wrinkles. *REV LARYNGOL OTOL RHINOL (BORD)*. 2006;127(1-2):105-11.
8. REDAELLI A, BRACCINI F. Medical Rhinoplasty. Basic principles and clinical practice. *OEO Firenze Ed*. 2010.
9. BRACCINI F, DOHAN EHRENFEST DM. Medical rhinoplasty: Rationale for atraumatic nasal modelling using botulinum toxin and fillers. *REV LARYNGOL OTOL RHINOL (BORD)*. 2008;129(4-5):233-8.
10. DAYAN SH, KEMPINERS JJ. Treatment of the lower third of the nose and dynamic nasal tip ptosis with Botox. *PLAST RECONSTR SURG*. 2005;115(6):1784-5.
11. BRACCINI F, et al. Mon nouveau nez. *Editions du losange*. 2006:112.
12. BRACCINI F, ROMAN O. La rhinoplastie. Une Re «nez» ssance. *Editions Ovidia*. 2012 (sous presse).